

# Newer Understanding of Specific Anatomic Targets in the Aging Face as Applied to Injectables: Superficial and Deep Facial Fat Compartments—An Evolving Target for Site-Specific Facial Augmentation

Smita R. Ramanadham, MD  
Rod J. Rohrich, MD  
*Boston, Mass.; and Dallas, Tex.*

**Summary:** The identification of specific fat compartments of the face has greatly improved the plastic surgeon's approach to facial rejuvenation. These superficial and deep compartments are discretely partitioned into multiple independent units by fascial barriers and undergo age-dependant volumetric changes. This knowledge has created a topographical map allowing for the direct and precise augmentation of those compartments that are deflated preferentially. These include the deep medial cheek, nasolabial, superficial middle, and lateral cheek compartments. Once this volume loss has been addressed, the overlying superficial musculoaponeurotic system and skin envelope can be treated to address laxity and bridge the compartments, creating a smooth cheek contour. Facial augmentation can be performed alone in the correct patient; however, it most often complements face-lifting. It is, therefore, important to have a thorough understanding of this anatomy and the changes that occur during aging. (*Plast. Reconstr. Surg.* 136: 49S, 2015.)

The knowledge of specific fat compartments of the face and age-related changes in facial fat distribution has improved the plastic surgeon's approach to facial rejuvenation. These compartments can be targeted precisely with fat or filler to restore a youthful appearance while consuming smaller amounts of material. It is apparent that the aging process is largely due to volume deflation, as described by V. Lambros (personal communication, July 2006). Volume loss occurs differentially within these compartments, resulting in facial contour incongruity. Termed "pseudoptosis," selective deflation of the deep cheek fat with age contributes to decreased projection of the superficial fat pads, resulting in an excess skin envelope and the illusion of ptosis.<sup>1,2</sup> This is in distinction to the youthful face, in which a smooth transition between compartments exists, resulting in an even contour.

Historically, the subcutaneous fat in the face was believed to be one confluent mass; therefore, facial rejuvenation procedures were based on lifting and repositioning this tissue as one single unit with manipulation of the skin and superficial musculoaponeurotic system (SMAS).<sup>3</sup> Focus was primarily placed on the treatment of the SMAS and skin in varying vectors and degrees of tightening. The evidence that this fat is compartmentalized, however, has allowed for differential restoration of facial volume in combination with rejuvenation through SMAS treatment if warranted.<sup>4</sup>

## FACIAL FAT COMPARTMENTS

To understand this mechanism, it is essential to review the anatomic studies by Rohrich and

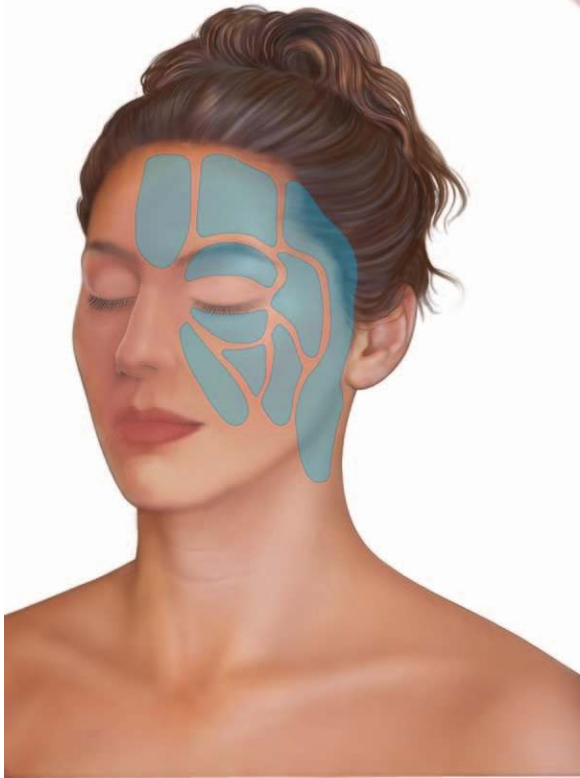*From the Division of Plastic and Reconstructive Surgery, Boston University School of Medicine; and Department of Plastic and Reconstructive Surgery, University of Texas Southwestern Medical Center.*

*Received for publication March 9, 2015; accepted July 10, 2015.*

*Copyright © 2015 by the American Society of Plastic Surgeons*

*DOI: 10.1097/PRS.0000000000001730*

**Disclosure:** *Dr. Rohrich receives instrument royalties from Eriem Surgical, Inc and book royalties from Quality Medical Publishing and Taylor and Francis Publishing. No funding was received for this article. Dr. Ramanadham has no financial information to disclose.*



**Fig. 1.** An artist's rendition of the subcutaneous compartments. Reprinted with permission from Rohrich RJ, Pessa JE. The fat compartments of the face: anatomy and clinical implications for cosmetic surgery. *Plast Reconstr Surg.* 2007;119:2219–2227.<sup>5</sup>

Pessa<sup>3,5,6</sup> and Rohrich et al.<sup>2</sup> This study elucidated a lattice of superficial and deep facial fat compartments discretely partitioned into multiple, independent units by fascial barriers (Figs. 1 and 2). Findings include the following:

**Nasolabial fat compartment:** Located anterior to the medial cheek fat and overlaps with the jowl. The orbicular retaining ligament (ORL) serves as its superior border, and it lies medial to the deep fat of the suborbicularis. The lower border of the zygomatic major is adherent to this compartment.

**Cheek fat compartments:** Composed of three components: medial, middle, and lateral temporal-cheek fat. The medial compartment lies lateral to the nasolabial fold, superior to the jowl fat, and inferior to the ORL and lateral orbital compartment. The middle fat compartment is superficial to the parotid gland. The dense fibrous abutment of the medial and middle fat compartment corresponds to the zygomatic ligament. The lateral temporal-cheek compartment is also superficial to the parotid and connects the temporal fat to the cervical subcutaneous fat.

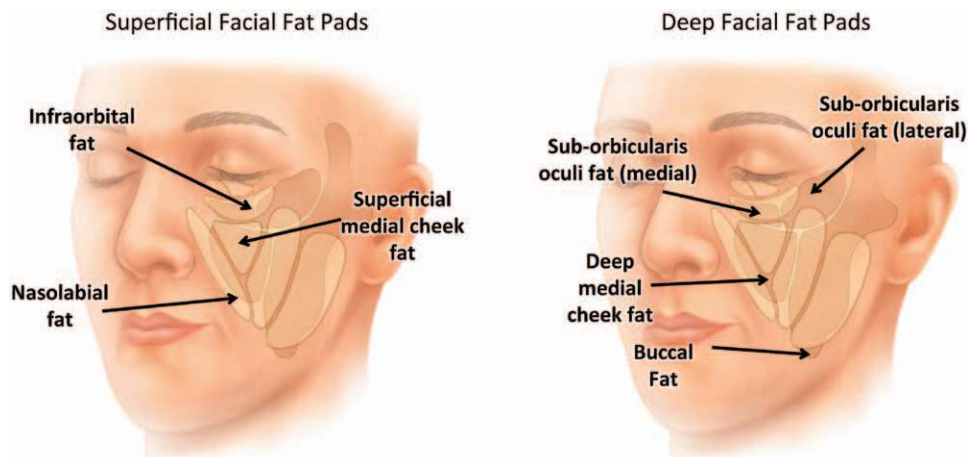
**Forehead and temporal fat compartment:** Includes a central compartment in the midline and the middle compartments just lateral to this bilaterally. The previously discussed lateral temporal-cheek compartment lies lateral to the middle compartments.

**Orbital fat compartment:** Composed of 3 compartments: the superior, inferior, and lateral compartments. The ORL, which is a circumferential structure, acts as a boundary for these structures.

**Jowl fat compartment:** Adheres to the depressor anguli oris. The medial boundary is the lip depressor, and inferior boundary is the membranous fusion of the platysma. This is separate and distinct from the nasolabial fat.

Deep compartments exist that lie below the SMAS, are anterior or posterior to the mimetic muscles, and enable sliding during animation or mastication<sup>5</sup> (Fig. 2). These include the suborbicularis oculi and oris, buccal fat pads, deep medial cheek fat, and lateral deep cheek compartment. This deep fat supports the overlying subcutaneous fat.<sup>2</sup> Deep fat loss occurs in the temporal and deep medial cheek fat, which is deep to the superficial middle and medial fat compartments.<sup>3</sup> This compartment lies anterior to the periosteum of the maxilla and Ristow's space. It is distinct from the suborbicularis oculi fat and lies inferior to the ORL. Furthermore, this compartment was noted to have 2 components, medial and lateral deep cheek compartment, both lying medial to the zygomaticus major muscle.<sup>2</sup> The most medial portion abuts the pyriform and the lateral lies over the maxilla supporting the overlying subcutaneous fat. Loss of volume in this compartment results in a loss of anterior midface projection, a prominent nasolabial fold, and a V-deformity of the lower lid.<sup>2</sup> Injection into this one compartment was found to restore a natural appearing cheek and efface the nasolabial fold and nasojugal trough.<sup>2</sup> In addition, the observation that the lateral cheek becomes irregular with age aided in the identification of a lateral deep compartment, superficial to the masseter, which when restored can improve this contour.<sup>2</sup>

The facial fat compartments are partitioned by a fibrous condensation of connective tissue, which originates from the underlying fascia to dermis and carries the perforator blood supply to the skin.<sup>3,7</sup> These fascial ligaments limit shearing forces on the face, thereby creating a “retaining system,” and provide stability for the vascular supply to the face.<sup>3,7</sup> Fat compartments stay within



**Fig. 2.** Schematics of facial adipose tissue anatomy. Schematic depiction of the superficial (*left*) and deep (*right*) facial fat compartments. Reprinted with permission from Wan D, Amirlak B, Giessler P, et al. The differing adipocyte morphologies of deep versus superficial midfacial fat compartments: a cadaveric study. *Plast Reconstr Surg.* 2014;133:615e–622e.<sup>1</sup>

these fascial boundaries, supporting the notion of deflation and pseudoptosis.<sup>2</sup>

Physiologic age-related changes in facial fat distribution have been further elucidated by the study by Gierloff et al.<sup>8</sup> Computed tomographic scans of cadaver heads confirmed the compartments described by Rohrich and Pessa and further elucidated the medial and lateral components of the deep medial cheek fat.<sup>5</sup> The medial component lies posterior to the nasolabial fold and the lateral lies posterior to the superficial medial cheek compartment. In addition, the buccal extension of the buccal fat pad was identified as a separate, discrete compartment. They demonstrate 2 key findings: an inferior migration of the midfacial fat compartments during aging as evidenced by increased distances between the compartments and infraorbital rim and an inferior volume shift within the compartments. The inferior migration, attributed to gravity and volume loss of the buccal extension of the buccal fat pad, contributes to the crescent-shaped hollow beneath the orbicularis oculi, deepening of the nasojugal and nasolabial fold and overall lack of support for the medial and middle cheek fat. In addition, a decrease in volume in the cephalad portions of the nasolabial and deep medial cheek compartments worsen the appearance of the tear trough, nasojugal fold, and palpebromalar groove.<sup>8</sup>

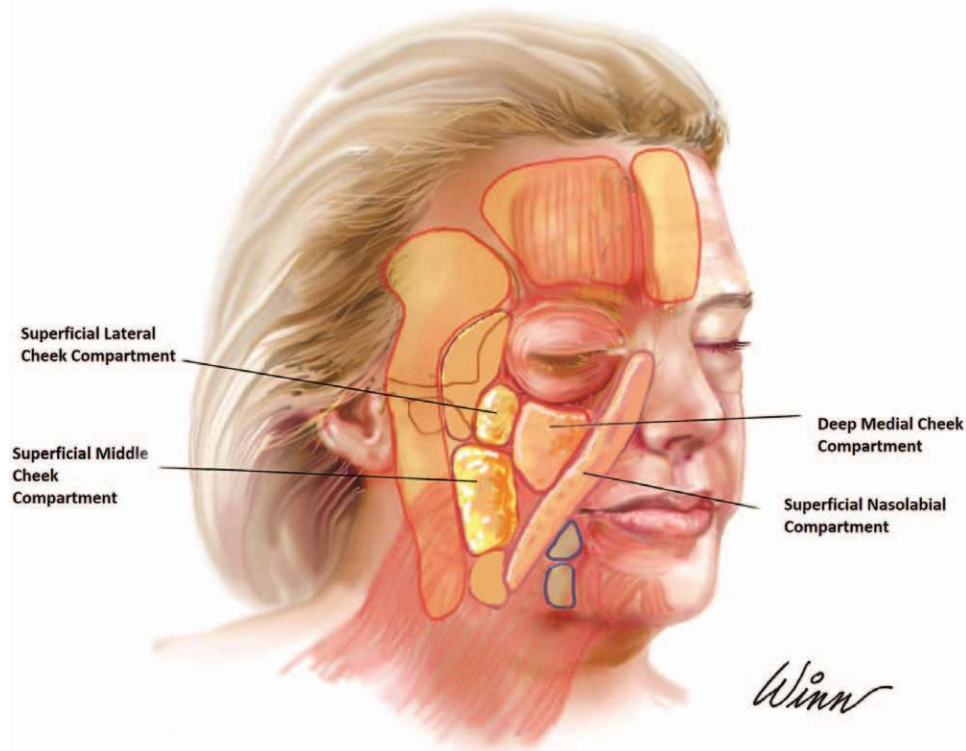
These findings support the notion that facial rejuvenation should center on 2 key concepts: volume restoration of specific compartments and facial contouring. This is not a new concept with B. Ristow (personal communication, September

2001) describing direct injection of autologous fat directly into the deep cheek fat in 2001.<sup>2</sup> Effects are immediate, resulting in improved anterior projection, decreased nasolabial fold, and corrected V-deformity, tear trough, and nasojugal fold of the lower lid creating a youthful cheek and lid-cheek junction.<sup>2</sup> Augmentation into these specific compartments allows for an increased ability to precisely restore facial volume with improved control and precision. The most important and relevant compartments to restore in facial rejuvenation include the deep medial cheek compartment (medial and lateral components) and the nasolabial fat compartment. The superficial middle and lateral cheek compartment can be filled for final contour improvement (Fig. 3).<sup>4,9</sup> This can be performed alone in young patients with minimal skin laxity or as a complement to SMAS and skin manipulation.<sup>3</sup>

### AUGMENTATION ALONE

In addition to fat or collagen products, multiple synthetic fillers have been developed with varying biophysical properties. The most popular of which include the class of hyaluronic acid (HA)-based fillers. These include Restylane (QMed/Galderma, Uppsala, Sweden; Medicis/Valeant, Bridgewater, N.J.); Juvederm Ultra, Ultra Plus, Voluma (Allergan, Inc., Irvine, Calif.); Perlane (QMed/Galderma); Prevalle Silk (Genzyme Corp., Cambridge, Mass.; Mentor Corp., Santa Barbara, Calif.); and Belotero (Merz Pharmaceuticals, Greensboro, N.C.). These fillers differ in their type and degree of cross-linking, viscosity,

## 4 Key Compartments- Deep and Superficial



**Fig. 3.** Key fat compartments for augmentation. Reprinted with permission from Rohrich RJ, Gha-vami A, Constantine FC, et al. Lift-and-fill face lift: integrating the fat compartments. *Plast Reconstr Surg.* 2014;133:756e–767e.<sup>4</sup>

stiffness ( $G'$ ), affinity for water, and HA concentration. Properties of fillers should be taken into consideration during placement within various compartments based on the depth and location of these compartments. Although the specific cross-linking process and biophysical properties for each filler are beyond the scope of this article, in general, fillers with increased stiffness (elastic modulus,  $G'$ ) and viscosity (ie, Voluma) are ideally used in the midface or in deeper locations, where visibility is less of a concern and tissue lift is necessary. Fillers with lower  $G'$  values (ie, Belotero), however, are softer and tend to spread more after implantation. This is helpful in more superficial areas, such as the lips or lower lids, where palpability is less desired and some filler spread may be ideal.<sup>10</sup>

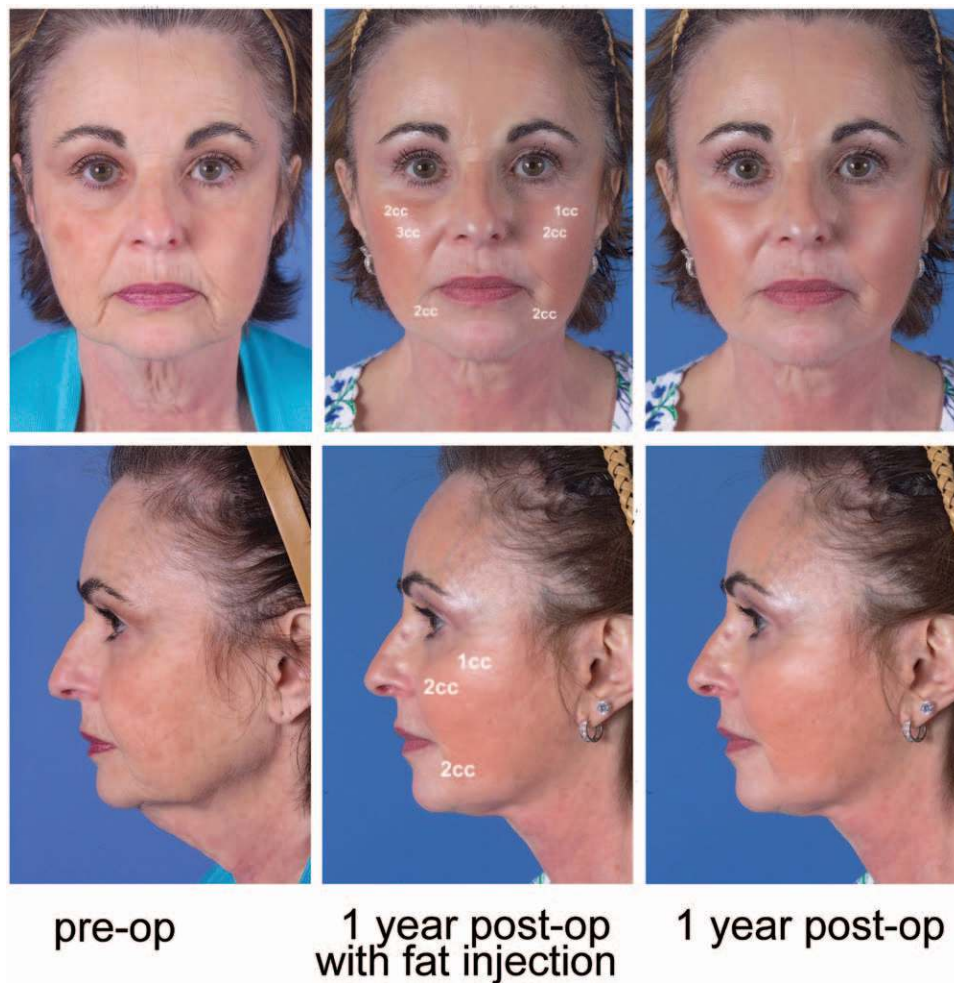In addition, HA products absorb water after injection based on their HA concentration. Those with typical degrees of cross-linking and approximately 5.5 mg/mL in concentration are close to their equilibrium and, therefore, absorb less. Those with higher concentrations of 20–24 mg/mL of HA are below equilibrium

hydration and swell once injected as they take up water. Generally, it is advantageous to choose fillers slightly below their equilibrium to add to the desired volumizing effect; this, however, may not be ideal in sensitive areas such as the lower lid.<sup>11</sup>

The knowledge of facial anatomy and ability to recognize which fat compartments have lost volume enables site-specific placement of the filler. Fillers can be chosen specifically for each area of injection based on their properties; this leads to specific, predictable, and natural-appearing results.<sup>12</sup>

### AUGMENTATION AND SMAS MANIPULATION

The synergistic effects of augmentation of the compartments and SMAS manipulation are invaluable in achieving facial harmony. SMAS manipulation additionally can alter and reposition the superficial fat compartments that lie above the SMAS. This was evaluated in a recent review of 100 patients who underwent individualized component face-lift, as described



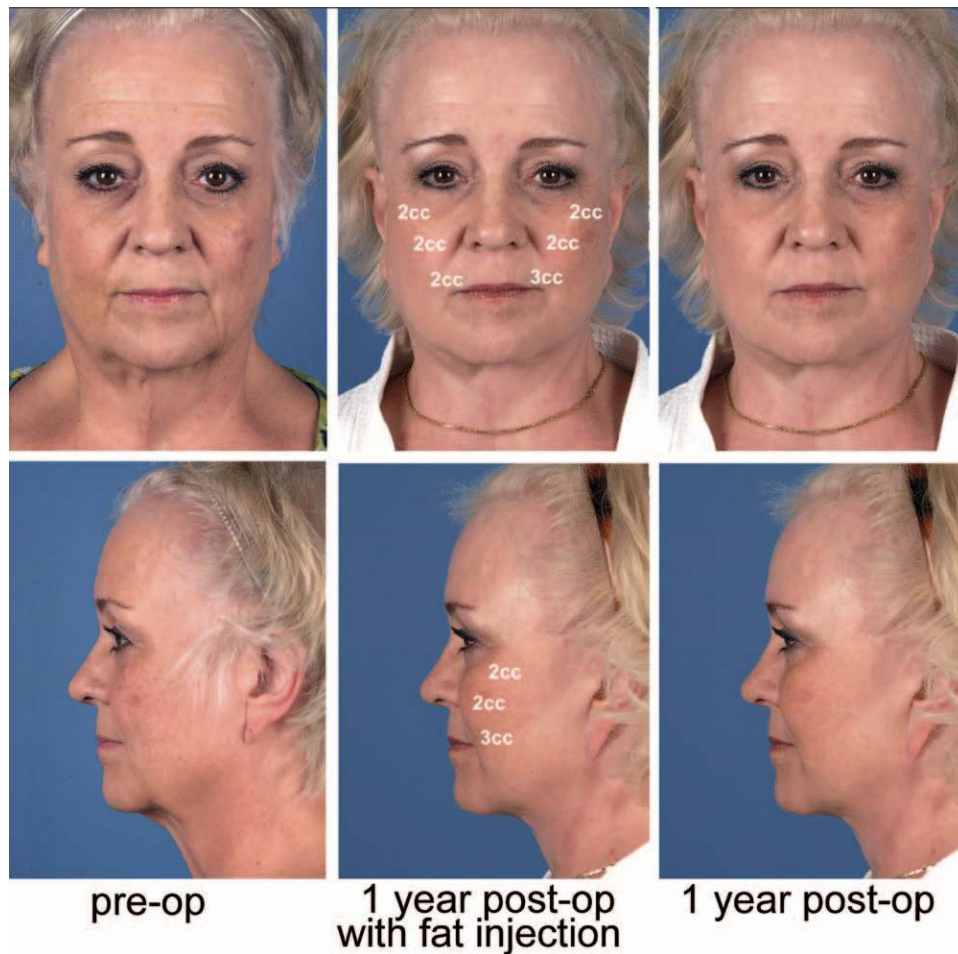**Fig. 4.** Case 1: Preoperative and postoperative views. Reprinted with permission from Rohrich RJ, Ghavami A, Constantine FC, et al. Lift-and-fill face lift: integrating the fat compartments. *Plast Reconstr Surg.* 2014;133:756e–767e.<sup>4</sup>

previously,<sup>9</sup> with fat grafting to the nasolabial fold compartment, deep medial cheek compartment, and superficial middle and lateral cheek fat compartments.<sup>4</sup> Fat was harvested from the abdomen or thighs and centrifuged. Injection was performed prior to face-lift into specific fat compartments based on preoperative facial analysis. SMAS manipulation was then served as a bridge between the deep and superficial compartments improving overall contour. Malar projection and lift, and nasolabial folds and malar grades, improved based on photographic analysis, suggesting the lift and fill technique addresses both deflation and the skin laxity. In these cases, it is important to realize that fat survival is not completely predictable and is variable due to future weight loss or gain. Given this, rather than overfilling the face, the patient should be counseled that postoperative injection of fillers

or fat superficially or directed into the fat compartments may be warranted for maintenance.<sup>4</sup>

## DISCUSSION

Volume restoration is not a new concept in facial rejuvenation.<sup>2</sup> The detailed anatomic descriptions of the facial fat compartments have added to our understanding of these concepts and have created a topographical map that allows for precise location, depth, and evaluation of volume deflation.<sup>4</sup> The deep medial cheek, nasolabial, superficial middle, and lateral cheek compartments are the most relevant to address. The deep medial cheek fat is composed of smaller adipocytes and tends to deflate at a higher rate. It is, therefore, critical to fill this compartment first to set the foundation to later build upon through SMAS manipulation and injection of the superficial compartments.<sup>4</sup> The ultimate goal



**Fig. 5.** Case 2: Preoperative and postoperative views. Reprinted with permission from Rohrich RJ, Ghavami A, Constantine FC, et al. Lift-and-fill face lift: integrating the fat compartments. *Plast Reconstr Surg.* 2014;133:756e–767e.<sup>4</sup>

is for augmentation to complement face-lifting techniques and is an adjunct to repositioning.

## CASE REPORTS

### Case 1

A 60-year-old woman underwent a lift and fill face-lift. Volume depletion is noted in the midface with loss of projection of the cheek and presence of nasolabial and nasojugal folds. Fat grafting volumes were depicted in Figure 4. Bilateral SMAS stacking was performed based on individualized component face-lift analysis.

### Case 2

A 62-year-old woman underwent a lift and fill face-lift with open necklift. Volume loss is noted in deep cheek compartment manifested by loss in anterior midface projection and deep nasojugal and nasolabial folds with loss of smooth lid-cheek junction. Fat was injected as indicated in Figure 5, specifically addressing the deep cheek fat compartment. Bilateral SMASectomy was performed based on the individualized component face-lift analysis to minimize facial fullness.

## CONCLUSIONS

Current understanding of facial fat compartments and their inferior migration and volume shift has allowed the plastic surgeon to specifically address volume loss by directly augmenting those that are deflated preferentially. Fat or fillers act as an adjunct to SMAS manipulation to rejuvenate the aging face.

*Smita R. Ramanadham, MD*

Division of Plastic and Reconstructive Surgery  
Boston University School of Medicine  
720 Harrison Avenue, Suite 9600  
Boston, Mass. 02118  
smita.ramanadham@bmc.org

## PATIENT CONSENT

*Patients provided written consent for the use of their images.*

REFERENCES

1. Wan D, Amirlak B, Giessler P, et al. The differing adipocyte morphologies of deep versus superficial midfacial fat compartments: a cadaveric study. *Plast Reconstr Surg.* 2014;133:615e–622e.
2. Rohrich RJ, Pessa JE, Ristow B. The youthful cheek and the deep medial fat compartment. *Plast Reconstr Surg.* 2008;121:2107–2112.
3. Rohrich RJ, Pessa JE. The retaining system of the face: histologic evaluation of the septal boundaries of the subcutaneous fat compartments. *Plast Reconstr Surg.* 2008;121:1804–1809.
4. Rohrich RJ, Ghavami A, Constantine FC, et al. Lift-and-fill face lift: integrating the fat compartments. *Plast Reconstr Surg.* 2014;133:756e–767e.
5. Rohrich RJ, Pessa JE. The fat compartments of the face: anatomy and clinical implications for cosmetic surgery. *Plast Reconstr Surg.* 2007;119:2219–2227.
6. Rohrich RJ, Pessa JE. The anatomy and clinical implications of perioral submuscular fat. *Plast Reconstr Surg.* 2009;124:266–271.
7. Schaverien MV, Pessa JE, Rohrich RJ. Vascularized membranes determine the anatomic boundaries of the subcutaneous fat compartments. *Plast Reconstr Surg.* 2009;123:695–700.
8. Gierloff M, Stöhring C, Buder T, et al. Aging changes of the midfacial fat compartments: a computed tomographic study. *Plast Reconstr Surg.* 2012;129:263–273.
9. Rohrich RJ, Ghavami A, Lemmon JA, et al. The individualized component face lift: developing a systematic approach to facial rejuvenation. *Plast Reconstr Surg.* 2009;123:1050–1063.
10. Sundaram H, Cassuto D. Biophysical characteristics of hyaluronic acid soft-tissue fillers and their relevance to aesthetic applications. *Plast Reconstr Surg.* 2013;132(4 Suppl 2):5S–21S.
11. Tezel A, Fredrickson GH. The science of hyaluronic acid dermal fillers. *J Cosmet Laser Ther.* 2008;10:35–42.
12. Fitzgerald R, Rubin AG. Filler placement and the fat compartments. *Dermatol Clin.* 2014;32:37–50.